

1973

## Lymphocystis in fish from east African lakes

Ilan Paperna

*Virginia Institute of Marine Science*

Follow this and additional works at: <https://scholarworks.wm.edu/vimsarticles>



Part of the [Marine Biology Commons](#)

---

### Recommended Citation

Paperna, Ilan, Lymphocystis in fish from east African lakes (1973). *Journal of Wildlife Diseases*, 9, 331-335.

<https://scholarworks.wm.edu/vimsarticles/2129>

This Article is brought to you for free and open access by the Virginia Institute of Marine Science at W&M ScholarWorks. It has been accepted for inclusion in VIMS Articles by an authorized administrator of W&M ScholarWorks. For more information, please contact [scholarworks@wm.edu](mailto:scholarworks@wm.edu).

## LYMPHOCYSTIS IN FISH FROM EAST AFRICAN LAKES<sup>1</sup>

I. PAPERNA<sup>2</sup>

**Abstract:** Lymphocystis is described for the first time from Africa. Lymphocystis infected cells formed clusters on the tails of cichlid fishes from East African lakes. Small rounded inclusion bodies and many large vacuoles were observed in the cytoplasm of the hypertrophied cells.

### INTRODUCTION

This is the first record of lymphocystis from Africa or from African freshwater fish and the second report of lymphocystis occurring in fishes of the family Cichlidae. Weissenberg<sup>5</sup> previously described a case of lymphocystis infection from a Central American cichlid.

### MATERIALS AND METHODS

Live fish were fixed in 10% formalin. The clusters of lymphocystis-infected cells were removed from the preserved fish and embedded in paraffin for histological studies. Seven  $\mu$  sections were stained in either Mayer's haemalum-eosin, Harris' hematoxylin-eosin or Heidenhain's Azan (Heidenhain's Azocarmine-Aniline Blue) using methods recommended by McManus and Mowery.<sup>3</sup> Sections were also stained by the Feulgen method and in methyl green-pyronin using times and temperatures recommended by McManus and Mowery.<sup>3</sup>

### RESULTS

#### Hosts and Distribution

Large clusters of hypertrophied lymphocystis cells were seen on the tails of juvenile *Tilapia amphimelas* and *T. esculenta* from Lake Kitangiri (North Tanzania) and on the tails of two juvenile *T. variabilis* (out of 265 checked) and two mature *Haplochromis* sp. (out of 98

checked) from northern Lake Victoria. Mild infections with fewer hypertrophied cells were also observed on the tails of two other juvenile *T. variabilis* and six mature *Haplochromis* sp. from northern Lake Victoria and also on one mature *H. elegans* (out of 95 checked) from Lake George. Infections on *T. variabilis* were observed on fish 30-39 mm in length and only during February, 1971. This restricted time of occurrence was not observed in *Haplochromis* spp.

#### Description

Clusters of cells measured up to 5 mm in diameter and contained as many as 200 rounded cells, 260-330  $\mu$  in diameter (Figs. 1, 2). The clusters were embedded in granulation tissue, under a layer of epithelium. The cells were surrounded by a thick eosinophilic capsular wall staining blue in Azan. Each cluster seemed to include only large, fully differentiated cells (Fig. 3). The cytoplasm of the hypertrophied cells contained either numerous large vacuoles, occasionally with small intravacuolar bodies, (Figs. 4, 5, 9), or, in a few cells, oval to rounded inclusion bodies with a basophilic reticulum or granulation (Figs. 6, 7, 8). The nuclei of all cells appeared to be in various degrees of disintegration, vesicular in appearance, lined with basophilic reticulum, and contained fragments of the presumptive nucleolus which were basophilic and stained deep orange in Azan (Figs. 4, 9). In a few cells the nucleus had disappeared and the nucleo-

<sup>1</sup> Contribution No. 550 from the Virginia Institute of Marine Science, Gloucester Point, Virginia 23062.

<sup>2</sup> Present address: The H. Steinitz Marine Biological Laboratory, Eilat, Israel.

lar fragments were scattered throughout the cell. Basophilic material also appeared in the cytoplasm as a scattered diffuse reticulum, fine granules, granular chains, or small square bodies 4-5  $\mu$  across. These basophilic structures appeared in vacuolated cells as well as in non-vacuolated cells which contained distinct inclusion bodies. Staining by the

Feulgen method and methyl green-pyronin were unsatisfactory and inconclusive (perhaps because the tissue was fixed in non-neutralized formalin) and the DNA positive colors of the stains were diffused throughout the cell cytoplasm rather than being limited to the inclusion bodies.




FIGURE 1. *Tilapia amphilelas* from Lake Kitangiri infected with lymphocystis.

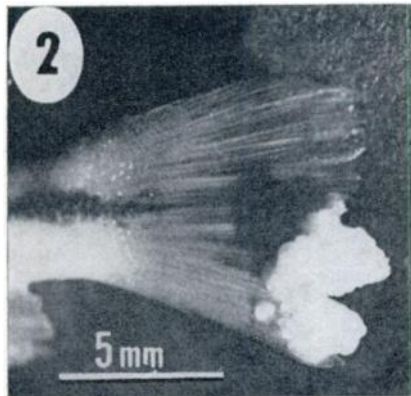


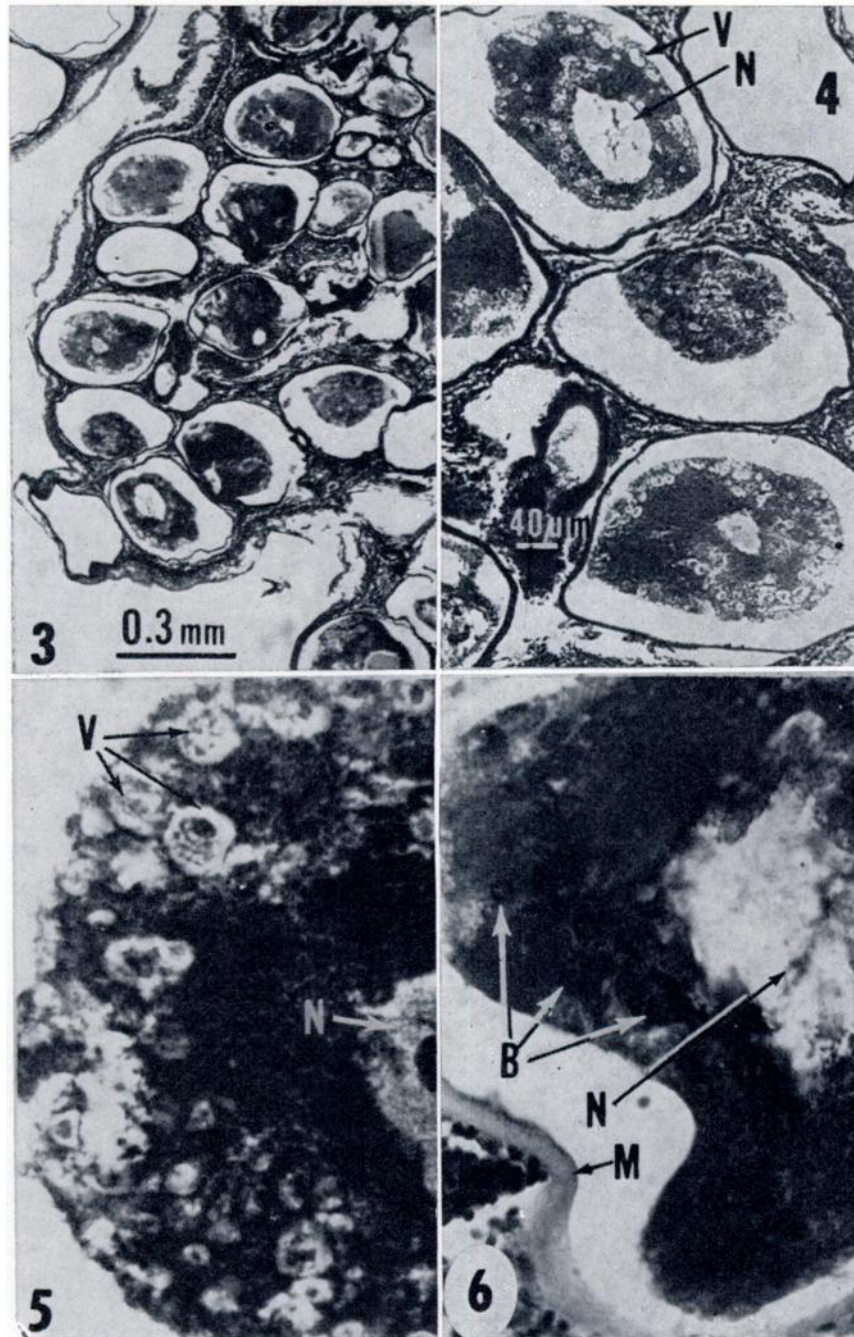
FIGURE 2. Tail of *Haplochromis* sp. from Lake Victoria (Entebbe) showing cluster of lymphocystis cells.

FIGURE 3. Cross section through lymphocystis cell cluster from *Haplochromis* sp. from Lake Victoria; Mayer's haemalum-eosin (X40).

FIGURE 4. Lymphocystis infected cells with vacuoles: N-nucleus; V-vacuoles, Heidenheim's Azan (X100).

FIGURE 5. Enlarged area of a cell showing vacuoles (V) and nucleus (N); Mayer's haemalum-eosin (X450; for scale see Fig. 8).

FIGURE 6. Enlarged area of a cell showing basophilic inclusion bodies; B-inclusion bodies; M-capsule wall; N-nucleus; Mayer's haemalum-eosin (X450; for scale see Fig. 8).



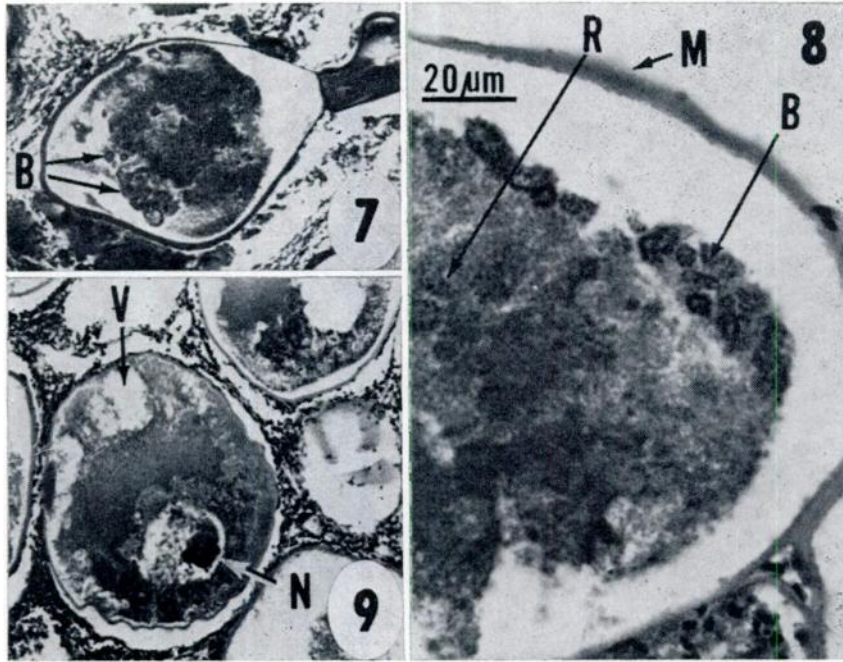


FIGURE 7. Lymphocystis-infected cell with inclusion bodies (B). Mayer's haemalum-eosin (X100; scale same as in Fig. 4).

FIGURE 8. Enlarged area of a cell containing basophilic inclusion bodies (B) with basophilic reticulum (R) Mayer's haemalum-eosin (X450).

FIGURE 9. Lymphocystis-infected cell containing large vacuoles (V). Note the nucleolus in the nucleus (N). Mayer's haemalum-eosin (X100; same scale as in Fig. 4).

#### DISCUSSION

Weissenberg<sup>5</sup> suggested that this type of lymphocystis with scattered inclusion bodies and large vacuoles is peculiar to infections in Cichlidae. Lymphocystis cells from African cichlids differ from lymphocystis cells previously described from such fish as *Stizostedion vitreus*, *Pleuronectes flesus*, *Lepomis macrochirus*, or *Morone saxatilis*<sup>1,2,4</sup> (and author's unpublished data) in the following respects:

a) The presence of numerous large vacuoles in the cytoplasm, in a majority of the hypertrophied cells.

b) The absence of large distinct basophilic inclusion bodies or plates. Inclusion bodies of a peculiar rounded shape and reticular texture occur only in the few, non-vacuolated cells; some of the vacuolated cells, however contained diffuse cytoplasmic basophilic material.

c) Cells are smaller (260-330 μ) than the cells described from *P. flesus* or *S. vitreus*, which can reach a diameter of 700 μ.

The described cells show similarities in structure with lymphocystis cells described by Weissenberg<sup>5</sup> from the South

American cichlid *Cichlasoma synspilum*. The vacuolated cells are similar to the description of Weissenberg's lymphocystis cells of classes III and IV, and the cells containing the inclusion bodies agree with features found in class V cells. A few cells similar to Weissenberg's class VI cells contained only diffuse basophilic material without vacuoles.

**Acknowledgement:**

I wish to thank Dr. F. Perkins and Mr. D. Zwerner, of Virginia Institute of Marine Sciences for reading and criticizing the manuscript.

**LITERATURE CITED**

1. DUNBAR, C. E. and KEN WOLF. 1966. The cytological course of experimental lymphocystis in the bluegill. *J. Inf. Dis.* 116:466-472.
2. KRANTZ, G. E. 1970. Lymphocystis in striped bass, *Roccus saxatilis*, in Chesapeake Bay. *Chesapeake Sci.* 11:137-139.
3. McMANUS, J. F. H. and R. W. MOWERY. 1960. *Staining Methods*. Paul B. Hoeber, Inc. N.Y. 423 p.
4. WEISSENBERG, R. 1965. Fifty years of research on the lymphocystis virus of fishes (1914-1964). *Ann. N.Y. Acad. Sci.* 126:362-372.
5. WEISSENBERG, R. 1965. Morphological studies on lymphocystis, tumor cells of cichlid from Guatemala, *Cichlasoma synspilum* Hubbs. *Ann. N.Y. Acad. Sci.* 126:396-413.

*Received for publication 30 March 1973*

---