

# Liver carcinogenesis in a non-migratory fish: The association with polycyclic aromatic hydrocarbon exposure

W.K. Vogelbein\* and M.A. Unger

*Department of Environmental and Aquatic Animal Health, Virginia Institute of Marine Science, The  
College of William and Mary, Gloucester Point, Virginia.*

## Abstract

Field and laboratory studies indicate a strong positive association between exposure to chemical pollutants in aquatic environments and development of neoplasia in fishes. This brief communication reviews some of the more important North American and European studies that have been conducted on this relationship. We then review work conducted on a small non-migratory estuarine cyprinodontid teleost fish, the mummichog (*Fundulus heteroclitus*) in the industrialized Elizabeth River, Virginia USA. Histopathological surveys of mummichogs from variously degraded habitats indicate an association between PAH exposure and development of neoplasia. We have observed non-neoplastic lesions, preneoplasms and hepatic, biliary, exocrine pancreatic and vascular neoplasms in mummichogs inhabiting Virginia and Maryland estuaries. These lesions track a sediment PAH gradient with highest prevalence occurring in fish from PAH-contaminated sites in the industrialized portions of the Elizabeth River, Virginia. Liver metabolizing enzyme profiles typical of those observed in carcinogen-challenged laboratory rodents (e. g., depressed phase I enzymes, elevated phase II enzymes, elevated p-glycoprotein) provided additional support of a chemical etiology for the neoplasms occurring in these fish. Long-term laboratory exposure of mummichogs to creosote-contaminated sediments resulted in development of altered hepatocellular foci and hepatic neoplasms. Biomarkers of fish exposure and effects (e.g., CYP1A induction, bile FAC's, DNA adducts, liver histopathology) are presently used in the Puget Sound, Washington USA and Elizabeth River, Virginia USA to track long-term environmental recovery following habitat remediation.

Over the past 30 years, numerous field and laboratory studies in North America and Western Europe have been conducted on adverse health effects of chemical exposure in fishes. Field studies have shown that some wild fish populations inhabiting urbanized coastal waters can exhibit pathologies characteristic of exposure to chemical carcinogens. An important focus of these investigations has been the probable causal relationship between exposure to a group of

chemical pollutants called the polycyclic aromatic hydrocarbons (PAHs) and development of liver neoplasia in wild fishes. Additionally, laboratory studies have shown fishes to be susceptible to a broad variety of carcinogenic chemical compounds including the PAHs, eliciting neoplastic responses similar to those long documented in carcinogen-exposed laboratory rodents. Field and laboratory studies have shown that fishes possess phase I and II xenobiotic metabolizing

\* Corresponding author's email: wolf@vims.edu

enzymes, including the cytochrome P4501A (CYP1A) and glutathione-S-transferase systems, and that they can produce DNA-reactive carcinogenic metabolites. Other studies have demonstrated that sediment PAHs are bioavailable to fishes. An important result of these investigations has been the application of fishes as carcinogenicity bioassay organisms, environmental sentinels and models of human disease. This short review highlights the use of fishes as field sentinels and the growing evidence supporting a causal relationship between PAH exposure and development of liver neoplasia in wild fish populations. It then focuses on results of studies conducted with a small cyprinodontid teleost, the mummichog (*Fundulus heteroclitus*) in Virginia USA estuaries.

### **Polycyclic aromatic hydrocarbons**

Polycyclic aromatic hydrocarbons are ubiquitous environmental contaminants derived largely from the incomplete combustion of organic matter. Large complex organic molecules, PAHs are comprised of fused aromatic ring structures and often divided into two broad classes. Major sources of environmental contamination include industrial dischargers such as metal smelting facilities, wood treatment plants using creosote, oil refining operations and accidental spills of fuel oil, crude oils and other petroleum products. Atmospheric emissions from incineration and internal combustion engines (e. g., automobiles) and urban runoff represent another major source of PAH contamination to estuaries. In heavily industrialized sites, PAHs often co-occur with a variety of other chemical pollutants,

including heavy metals, chlorinated pesticides and polychlorinated biphenyls (PCBs) (Johnson et al., 2002).

The high molecular weight PAHs are extremely hydrophobic and sorb avidly to organic and inorganic matter. Thus, in aquatic environments, PAHs tend to bind detritus and become immobilized in bottom sediments, while concentrations in surface waters are generally very low (Johnson et al., 2002). Despite extensive and tenacious adsorption to sediments, PAHs appear to be readily bioavailable to aquatic organisms. Fishes are exposed to PAHs through their diet, by aqueous exposure and by direct contact with sediments (Meador et al., 1995a). Many benthic invertebrates, especially those that ingest sediment, can bioaccumulate PAHs and therefore, may constitute an important dietary source of PAH exposure in fishes (Meador et al., 1995b).

Although sediment PAHs are readily bioavailable and tend to bioaccumulate in some aquatic invertebrates, they do not normally accumulate to an appreciable degree within tissues of aquatic vertebrates such as teleost fishes. Additionally, there does not seem to be any significant biomagnification of PAHs across trophic levels in fishes (Suedel et al., 1994). Thus, measured PAH concentrations are generally very low in fish tissues and are not considered to be a useful method of assessing environmental exposure. The primary reason for this is that they rapidly and efficiently biotransform these hydrophobic contaminants into polar, more water soluble forms that are then more easily excreted. Xenobiotic metabolizing enzyme systems such as the CYP1As and glutathione-

S-transferases are responsible for biotransformation of xenobiotic chemicals in vertebrate animals. Thus these enzymes serve an important detoxication function and provide a mechanism whereby large hydrophobic and potentially toxic xenobiotics are eliminated from the tissues and the body. In vertebrates, the primary organ responsible for the metabolic detoxication of hydrophobic organic contaminants such as PAHs is the liver. This is most probably the reason why liver is a common target organ for the adverse effects of exposure to these chemical compounds.

Although they do not generally bioaccumulate in vertebrate tissues, PAHs have been documented to cause significant adverse health effects in exposed organisms. While metabolic conversion of PAHs serves mainly in detoxication of xenobiotics, some of the intermediate metabolites produced during this process exhibit potent cytotoxic, immunotoxic, mutagenic and carcinogenic properties. Recent investigations have shown that some PAHs including benzo[a]pyrene, benzfluoranthene, benz[a]anthracene, dibenz[a,h]anthracene, indeno[1,2,3-c,d]pyrene and dibenzo[a,l]pyrene are highly carcinogenic in laboratory rodents (e. g., NTP, 1999). Carcinogenic potential of some of these PAHs has been confirmed in fishes (e. g., Hawkins et al. 1990; 1995; Hendricks et al., 1985; Reddy et al., 1999). Additionally, most of these carcinogens have been documented at biologically significant concentrations in PAH contaminated aquatic sediments (Reddy et al., 1999).

### North American studies

In North America, epizootics of cancer have been documented in fishes from over 40 freshwater and estuarine waterways (Clark and Harshbarger, 1990), with several of them attributed to chemical contaminant exposure. The epizootics associated with exposure to carcinogens such as the PAHs have occurred mainly in benthic species and comprise largely liver neoplasia and neoplasia-related liver lesions. They include the winter flounder, *Pleuronectes americanus*, from Boston Harbor, MA (Moore and Stegeman, 1994; Moore et al., 1996), the brown bullhead, *Ictalurus nebulosus*, from tributaries of the southern Great Lakes region (Baumann, 1989; Baumann et al., 1991), the English sole, *Pleuronectes vetulus*, and other bottomfish species from Puget Sound, WA (Myers et al., 1987; 1998; Johnson et al., 2002), the tomcod, *Microgadus tomcod*, from the Hudson River estuary, NY (Smith et al., 1979) and the mummichog, *Fundulus heteroclitus*, from the Elizabeth River, VA (Vogelbein et al., 1990; 1997). PAHs have been implicated as causative agents in most of these epizootics and the prevalence of fish liver disease has been found to rise with increasing industrialization and urbanization. Liver lesion prevalences as high as 90% have been documented in fishes inhabiting waterways where sediment PAH concentrations are very high, while lesion prevalences have been very low or inconsequential (<1%) in fishes from relatively uncontaminated reference habitats (Vogelbein et al., 1990). Further, PAH concentrations in benthic invertebrate prey organisms and fish gut contents (Malins et al., 1984; Myers et al., 1987; 1993), induction of CYP1A and GST-mediated xenobiotic

metabolizing enzymes (e.g., Van Veld et al., 1991; 1992; 1997), DNA adduction in fish tissues (Varanasi et al., 1986), PAH metabolite levels in fish bile (Krahn et al., 1984) and P-glycoprotein expression (Cooper et al., 1999) all are reported to be much higher in fishes from PAH-contaminated environments than in fishes from relatively uncontaminated habitats. These findings strongly support the hypothesis that PAHs are bioavailable to fishes, that they are rapidly metabolized with certain metabolites causing mutations, and that they play an important causative role in the development of liver disease in some wild fish populations.

### European studies

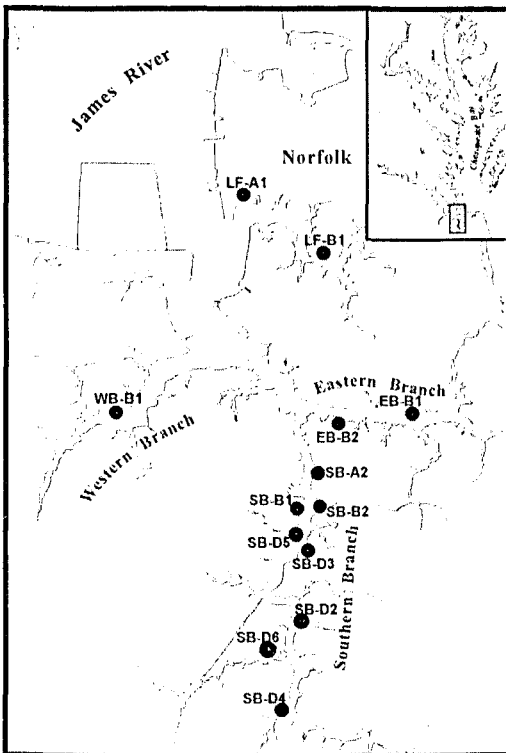
Field studies conducted in western European waters have found similar associations between environmental contaminants and development of liver neoplasia in flatfishes. Efforts in Europe have focused on the common dab, *Limanda limanda*, and the European flounder, *Platichthys flesus*. A spectrum of toxicopathic neoplastic, pre-neoplastic and non-neoplastic liver lesions, similar in most respects to the suite of lesions observed in North America, has been reported (Kranz and Dethlefsen, 1990; Kohler, 1991; Kohler et al., 1992; 2002; Bucke and Feist, 2003; Vethaak and Wester, 1996a; Stentiford et al., 2003). The utility of these histopathologic biomarkers as sensitive and reliable bio-indicators of health in wild fish populations has been demonstrated and their use has become established as a viable tool in European pollution monitoring programs (Feist et al., 2004).

### Laboratory evidence for a direct cause and effect

Direct experimental evidence that sediment PAHs cause liver neoplasia in wild fishes is scant. To date, the most direct evidence for this association has been provided by Metcalfe et al. (1988) who induced hepatocellular carcinomas in rainbow trout, *Oncorhynchus mykiss* by microinjecting fry with sediment extracts from Hamilton Harbor, Ontario, and by Schieve et al. (1991) who induced altered hepatocellular foci in English sole, exposed to an extract of a chemically contaminated marine sediment. Long-term sediment challenge studies have also been attempted in Europe. Mesocosm exposures of European flounders were conducted, but with only marginal success (Vethaak et al., 1996b). Few liver neoplasms were reported during this study.

### The mummichog, *Fundulus heteroclitus*: A case study

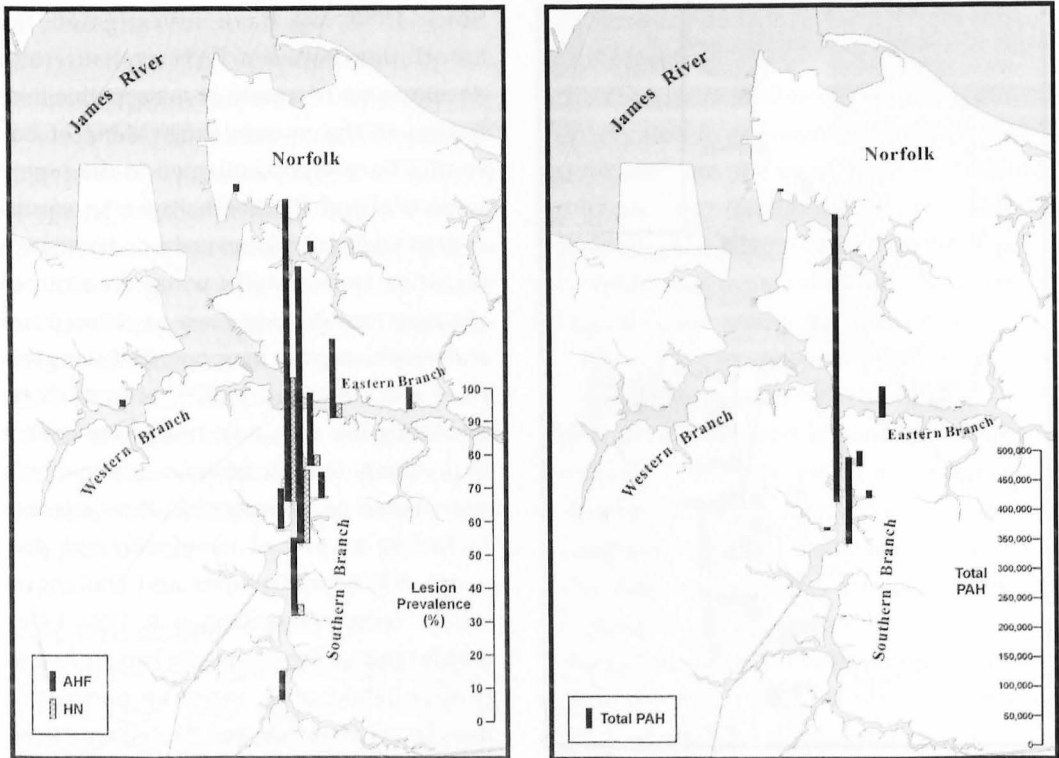
The mummichog, *Fundulus heteroclitus*, is a small estuarine cyprinodontiform teleost with a number of attributes suggesting it as a good sentinel of chemical contamination in Eastern USA estuaries. It has a wide geographic distribution, inhabiting coastal marshes from Nova Scotia to Florida (Bigelow and Schroeder, 1953). It is perhaps the most abundant intertidal marsh fish along the east coast and thus, relatively easy and inexpensive to collect. A very important attribute is that local sub-populations are non-migratory, exhibiting a summer home range on the order of 30-40 m (Lotrich, 1975) and greatly restricted winter movements (Fritz et al., 1975). This, suggests that local populations integrate a range of environmental variables and in effect,



**Figure 1.** Twelve sampling sites for collection of mummichogs (*Fundulus heteroclitus*) and sediment samples in the Elizabeth River, Virginia USA. Sixty adult fish and three replicate surficial sediment samples were collected at each site.

reflect the "health" of their immediate environment. They can thus be used effectively to evaluate adverse biological effects in restricted localized waters close to specific point source discharges. The mummichog is readily cultured in the laboratory and all life stages are hardy and amenable to experimental manipulation. The mummichog is currently the only known species exhibiting neoplasia in polluted environments that also is amenable to laboratory studies. It is therefore the best available model system to verify the putative cause-effect relationship between contaminant exposure and the development of liver pathology in wild fishes.

Since 1990, we have investigated the association between PAH exposure and development of a suite of toxicopathic liver lesions in the mummichog. Many of our studies have been conducted in the highly industrialized Elizabeth River, in southeastern Virginia USA. Several wood treatment facilities traditionally using creosote to pressure treat timbers such as railroad ties and telephone poles have operated along this river since the mid 1920's. Mummichogs inhabiting the inter-tidal near shore habitat in proximity to these facilities exhibit a high prevalence of toxicopathic liver disease including a suite of neoplastic and pre-neoplastic hepatocellular and cholangiocellular lesions (Vogelbein et al. 1990, 1999), a wide range of non-neoplastic hepatic lesions (unpublished obs), exocrine pancreatic neoplasms (Fournie and Vogelbein, 1994, Vogelbein and Fournie, 1994) and vascular neoplasms (Vogelbein et al., 1997). Hepatocellular lesions include a suite of altered hepatocellular foci (e.g., eosinophilic, basophilic, clear cell, vacuolated, and amphophilic foci), hepatocellular adenoma, hepatocellular carcinoma and hepatoblastoma (Vogelbein et al., 1990; Vogelbein et al., 1999). Cholangiocellular lesions include cholangiofibrosis, cholangioma and cholangiocarcinomas. Pancreatic neoplasms include acinar cell adenomas and carcinomas and vascular neoplasms include hemangioendothelioma, hemangiosarcoma and hemangiopericytic sarcoma (Vogelbein unpublished findings). Our field surveys within the Elizabeth River and in other chemically impacted parts of the Chesapeake Bay USA indicate a strong association between PAH exposure and toxicopathic liver



**Figure 2.** Fish liver histopathology and total sediment PAH concentrations from 12 sampling sites in the Elizabeth River, Virginia USA. 2a) Fish liver lesion prevalence for altered hepatocellular foci (AHF) and hepatic neoplasms (HN). Fish were processed for paraffin histology by routine methods. 2b) Total sediment PAH concentrations (ng/g dry weight). Sediments were analyzed by GC/ Mass Spectrometry.

disease, with liver lesion prevalence and severity tracking a sediment PAH gradient. Figure 1 illustrates our 12 study sites within the Elizabeth River system. Figures 2a and b illustrate the association between liver lesion prevalence in the mummichog and sediment PAH concentrations for these 12 sites. Note that both lesion prevalence for altered hepatocellular foci (AHF) and hepatic neoplasms (HN) and sediment PAH concentrations are highest in the heavily industrialized southern and eastern branches, whereas the western branch and Lafayette River is not impacted.

We have found that Elizabeth River mummichogs have developed a genetically based resistance to the acutely toxic components of creosote (Mulvey et al., 2002; 2003; Ownby et al., 2003). Because offspring of these fish are highly resistant to the acutely toxic components of creosote, this has provided us with an approach to conduct long-term (year-long) sediment exposure studies to evaluate the carcinogenicity of the river sediments near one of the wood treatment facilities. Following a yearlong sediment and dietary exposure regimen, fish developed a high (40%) prevalence of altered hepatocellular foci and a moderate level of hepatic neoplasms

(8.7%) (Vogelbein unpublished results). This has provided some of the strongest direct experimental evidence for a cause and effect relationship between chronic PAH exposure and fish neoplasia to date.

### Tracking environmental recovery following site remediation efforts

The most thorough investigations to date on the cause/effect relationship between PAH exposure and cancer development in wild fishes have been those conducted on the English sole in the Pacific Northwest. Myers et al. (2003) summarize an extensive 25-year database on the impacts of PAHs and related industrial contaminants on English sole and other benthic fishes. Statistical analyses of multiple field investigations dating back to 1978 identified exposure to PAH and, to a lesser degree chlorinated hydrocarbons such as polychlorinated biphenyls (PCBs), as highly significant major risk factors for the development of liver neoplasia and related lesions in this benthic species. These researchers are now using the English sole as an indicator species to track environmental recovery following remediation efforts in severely contaminated environments. Sampling conducted in Eagle Harbor, Puget Sound, USA subsequent to capping of a creosote-contaminated portion with clean dredge spoils, showed drastic declines in exposure to PAHs as measured by biliary PAH metabolites and hepatic DNA adducts in the fish. The decline in PAH exposure was accompanied by a dramatic decline in the prevalence of toxicopathic liver lesions in English sole over an eight year followup period. Similar studies to track environmental recovery following site remediation efforts are

currently planned in the Elizabeth River, Virginia. Because of their high site fidelity, mummichogs will be used at several sites within the industrialized portions of the river to monitor effectiveness of specific site remediation efforts.

### References

- Baumann PC (1989). PAH, metabolites, and neoplasia in feral fish populations. *In* "Metabolism of Polycyclic Aromatic Hydrocarbons in the Aquatic Environment" (U. Varanasi, Ed.), pp. 269-289. CRC Press, Inc., Boca Raton, Florida.
- Baumann PC, Mac MJ, Smith SB and Harshbarger JC (1991). Tumor frequencies in walleye (*Stizostedion vitreum*) and brown bullhead (*Ictalurus nebulosus*) and sediment contaminants in tributaries of the Laurentian Great Lakes. *Canadian Journal of Fisheries and Aquatic Sciences* **48**, 1804-1810.
- Bigelow HB and Schroeder WC (1953). Fishes of the Gulf of Maine. *Fisheries Bulletin* **53**, 1-577.
- Bucke D and Feist SW (1993). Histological changes in the livers of dab, *Limanda limanda* (L.) *Journal of Fish Diseases* **16**, 281-296.
- Clark JB and Harshbarger JC (1990). Epizootiology of neoplasms in bony fish from North America. *Science of the Total Environment* **94**, 1-32.
- Cooper PS, Vogelbein WK and van Veld PA (1999). Altered expression of the xenobiotic transporter P-glycoprotein in liver and liver tumors of mummichog (*Fundulus heteroclitus*) from a creosote-contaminated environment. *Biomarkers* **4**, 48-58.
- Fournie JW and Vogelbein WK (1994). Exocrine pancreatic neoplasms in the mummichog (*Fundulus heteroclitus*) from a creosote contaminated site. *Toxicologic Pathology* **22**(3), 237-247.

Feist SW, Lang T, Stentiford GD and Kohler A (2004). Biological effects of contaminants: Use of Liver pathology of the European flatfish dab (*Limanda limanda* L.) and flounder (*Platichthys flesus* L.) for monitoring. ICES Techniques in Marine Environmental Sciences No. 38. 42 pp.

Fritz ES, Meredith WH and Lotrich VA (1975). Fall and winter movements and activity level of the mummichog, *Fundulus heteroclitus*, in a tidal creek. *Chesapeake Science* 16, 211-215.

Hawkins WE, Walker WW, Overstreet RM, Lytle JS and Lytle TF (1990). Carcinogenic effects of some polynuclear aromatic hydrocarbons on the Japanese medaka and guppy in waterborne exposures. *Science of the Total Environment* 94, 155-167.

Hawkins WE, Walker WW and Overstreet RM (1995). Carcinogenicity tests using aquarium fish. *Toxicological Methods* 5, 225-263.

Hendricks JD, Meyers TR, Shelton DW, Casteel JL and Bailey GS (1985). Hepatocarcinogenicity of benzo[a]pyrene to rainbow trout by dietary exposure and intraperitoneal injection. *Journal of the National Cancer Institute* 74, 839-851.

Johnson LL, Collier TK and Stein JE (2002). An analysis in support of sediment quality thresholds for polycyclic aromatic hydrocarbons (PAHs) to protect estuarine fish. *Aquatic Conservation: Marine Freshwater Ecosystems* 12, 517-138.

Kohler A (1991). Lysosomal perturbations in fish liver as indicators for toxic effects of environmental pollution. *Comparative Biochemistry and Physiology* 100, 122-127.

Kohler A, Deisemann H and Lauritzen B (1992). Histological and cytochemical indices of toxic injury in the liver of dab *Limanda limanda* L. *Marine Ecology Progress Series* 92, 141-153.

Kohler A, Wahl E and Soeffker K (2002). Functional and morphological changes of lysosomes as prognostic biomarkers of toxic injury in a marine flatfish (*Platichthys flesus* (L.)). *Environmental Toxicology and Chemistry* 21(11), 2434-2444.

Krahn MM, Myers MS, Burrows DG and Malins DC (1984). Determination of metabolites of xenobiotics in the bile of fish from polluted waterways. *Xenobiotica* 16, 957-973.

Kranz H and Dethlefsen V (1990). Liver anomalies in dab *Limanda limanda* from the southern North Sea with special consideration given to neoplastic lesions. *Diseases of Aquatic Organisms* 9, 171-185.

Lotrich VA (1975). Summer home range and movements of *Fundulus heteroclitus* (Pisces: Cyprinodontidae) in a tidal creek. *Ecology* 56, 191-198.

Malins DC, McCain BB, Brown DW, Chan SL, Myers MS and Landahl JT (1984). Chemical pollutants in sediments and diseases of bottom-dwelling fish in Puget Sound, Washington. *Environmental Science and Technology* 18, 705-713.

Meador JP, Stein JP, Reichert WL and Varanasi U (1995a). A review of bioaccumulation of polycyclic aromatic hydrocarbons by marine organisms. *Reviews of Environmental Contamination and Toxicology* 143, 79-165.

Meador JP, Casillas E, Sloan CA and Varanasi U (1995b). Comparative bioaccumulation of polycyclic aromatic hydrocarbons from sediment by two infaunal invertebrates. *Marine Ecology Progress Series* 123, 107-124.

Metcalf CD, Cairns VW and Fitzsimons JD (1988). Experimental induction of liver tumors in rainbow trout (*Salmo gairdneri*) by contaminated sediment from Hamilton Harbor, Ontario. *Canadian Journal of Fisheries and Aquatic Sciences* 45, 2161-2167.

- Moore MJ and Stegeman JJ (1994). Hepatic neoplasms in winter flounder, *Pleuronectes americanus* from Boston Harbor, Massachusetts, USA. *Diseases of Aquatic Organisms* **20**, 33-48.
- Moore M, Shea D, Hillman RE and Stegeman JJ (1996). Trends in hepatic tumors and hydropic vacuolation, fin erosion, organic chemical and stable isotope ratios in winter flounder, *Pleuronectes americanus*, from Massachusetts, USA. *Marine Pollution Bulletin* **32**, 458-470.
- Mulvey M, Newman MC, Vogelbein WK and Unger MA (2002). Genetic structure of *Fundulus heteroclitus* from PAH-contaminated and neighboring sites along the Elizabeth River. *Aquatic Toxicology* **61**, 195-209.
- Mulvey M, Newman MC, Vogelbein WK, Unger MA and Ownby DR (2003). Genetic structure and mtDNA diversity of *Fundulus heteroclitus* populations from PAH-contaminated sites. *Environmental Toxicology and Chemistry* **22**(3), 1-7.
- Myers MS, Rhodes LD and McCain BB (1987). Pathologic anatomy and patterns of occurrence of hepatic neoplasms, putative preneoplastic lesions and other idiopathic hepatic conditions in English sole (*Parophrys vetulus*) from Puget Sound, Washington. *Journal of the National Cancer Institute* **78**, 333-363.
- Myers MS, Stehr CM, Olson OP, Johnson LL, McCain BB, Chan SL and Varanasi U (1993). National Benthic Surveillance Project: Pacific Coast, fish histopathology and relationships between toxicopathic lesions and exposure to chemical contaminants for Cycles I to V (1984-88). U.S. Dept. Commer., NOAA Tech. Memo. NMFS/NWFSC-6, 160 pp.
- Myers MS, Johnson LL, Olson OP, Stehr CM, Horness BH, Collier TK and McCain BB (1998). Toxicopathic hepatic lesions as biomarkers of chemical contaminant exposure and effects in marine bottomfish species from the Northeast and Pacific coasts, USA. *Marine Pollution Bulletin* **37**, 92-113.
- Myers MS, Johnson LL and Collier TK (2003). Establishing the causal relationship between polycyclic aromatic hydrocarbon (PAH) exposure and hepatic neoplasms and neoplasia-related liver lesions in English sole (*Pleuronectes vetulus*). *Human and Ecological Risk Assessment* **9**(1), 68-93.
- National Toxicology Program. 1999. The Ninth Report on Carcinogens. U.S. Department of Health and Human Services, Public Health Service National Toxicology Program. Washington, D.C.
- Ownby DR, Newman MC, Mulvey M, Vogelbein WK, Unger MA and Arzayus LF (2002). Fish (*Fundulus heteroclitus*) populations with different exposure histories differ in tolerance of creosote-contaminated sediments. *Environmental Toxicology and Chemistry* **21**, 1897-1902.
- Reddy AP, Spitsbergen JM, Mathews C, Hendricks JD and Bailey GS (1999). Experimental hepatic tumorigenicity by environmental hydrocarbon dibenzo[a,l]pyrene. *Journal of Environmental Pathology, Toxicology and Oncology* **18**(4), 261-269.
- Schieve MS, Weber DD, Myers MS, Jaques FJ, Riechert WL, Krone CA, Malins DC, McCain BB, Chan SL and Varanasi U (1991). Induction of foci of cellular alteration and other hepatic lesions in English sole (*Parophrys vetulus*) exposed to an extract of an urban marine sediment. *Canadian Journal of Fisheries and Aquatic Sciences* **48**, 1750-1760.
- Stentiford GD, Longshaw M, Lyons BP, Jones G, Green M and Feist SW (2003). Histological biomarkers in estuarine fish species for the assessment of biological effects of contaminants. *Marine Environmental Research* **55**, 137-159.
- Smith CE, Peck TH, Klauda RJ and McLaren JB (1979). Hepatomas in Atlantic tomcod *Microgadus tomcod* (Walbaum) collected in the Hudson River estuary in New York. *Journal of Fish Diseases* **2**, 313-319.

- Suedel BC, Boraczek JA, Peddicord RK, Clifford PA and Dillon TM (1994). Trophic transfer and biomagnification potential of contaminants in aquatic ecosystems. *Reviews of Environmental Contamination and Toxicology* **136**, 22-89.
- Van Veld PA, Ko U, Vogelbein WK and Westbrook DJ (1991). Glutathione S-transferase in intestine, liver, and hepatic lesions of mummichog (*Fundulus heteroclitus*) from a creosote-contaminated environment. *Fish Physiology and Biochemistry* **9**(4), 369-376.
- Van Veld PA, Vogelbein WK, Cochran MK, Goksoyr A and Stegeman JJ (1997). Route-specific cellular expression of cytochrome P4501A (CYP1A) in fish (*Fundulus heteroclitus*) following exposure to aqueous and dietary benzo[a]pyrene. *Toxicology and Applied Pharmacology* **142**, 348-359.
- Van Veld PA, Vogelbein WK, Smolowitz R, Woodin BR and Stegeman JJ (1992). Cytochrome P450IA1 in hepatic lesions of a teleost fish (*Fundulus heteroclitus*) collected from a polycyclic aromatic hydrocarbon-contaminated site. *Carcinogenesis* **13**(3), 505-507.
- Varanasi U, Nishimoto M, Reichert WL and Le Eberhart BT (1986). Comparative metabolism of benzo[a]pyrene and covalent binding to hepatic DNA in English sole, starry flounder, and rat. *Cancer Research* **46**, 3817-3824.
- Vethaak AD and Wester PW (1996a). Disease of flounder *Platichthys flesus* in Dutch coastal and estuarine waters with particular reference to environmental stress factors. II. Liver histopathology. *Diseases of Aquatic Organisms* **26**, 99-116.
- Vethaak AD, Jol JG, Meijboom A, Eggens ML, Rheinallt T, Wester PW, van de Zande T, Bergman A, Dankers N, Ariese F, Bann RA, Everts JM, Opperhuizen A and Marquenie JM (1996b). Skin and liver diseases induced in flounder (*Platichthys flesus*) after long-term exposure to contaminated sediments in large-scale mesocosms. *Environmental Health Perspectives* **104**, 1218-1229.
- Vogelbein WK, Fournie JW, Van Veld PA and Huggett RJ (1990). Hepatic neoplasms in the mummichog *Fundulus heteroclitus* from a creosote-contaminated site. *Cancer Research* **50**, 5978-5986.
- Vogelbein WK, Fournie JW, Cooper PS and Van Veld PA (1999). Hepatoblastomas in the mummichog, *Fundulus heteroclitus* (Linnaeus), from a creosote-contaminated environment: A histologic, ultrastructural, and immunohistochemical study. *Journal of Fish Diseases* **22**, 419-431.
- Vogelbein WK, Zwerner DE, Unger MA, Smith CL and Fournie JW (1997). Hepatic and extra-hepatic neoplasms in a teleost fish from a polycyclic aromatic hydrocarbon contaminated habitat in Chesapeake Bay, USA. In "Spontaneous Animal Tumors: A Survey" (L. Rossi, R. Richardson, and J. Harshbarger, Eds.) pp. 55-64.
- Vogelbein WK and Fournie JW (1994). The ultrastructure of normal and neoplastic exocrine pancreas in the mummichog, *Fundulus heteroclitus*. *Toxicologic Pathology* **22**(3), 248-260.